

Medical complications of pregnancy in hereditary haemorrhagic telangiectasia

C.L. SHOVLIN^{1,2}, A.R. WINSTOCK¹, A.M. PETERS³, J.E. JACKSON³ and J.M.B. HUGHES^{1,3}

From the ¹Department of Medicine, Royal Postgraduate Medical School, Hammersmith Hospital, London, ²Department of Genetics, Harvard Medical School, Boston, USA, and ³Department of Radiology, Royal Postgraduate Medical School, Hammersmith Hospital, London, UK

Received 20 March 1995; Accepted 13 April 1995

Summary

Hereditary haemorrhagic telangiectasia (HHT) displays significant variation in severity between affected individuals in the same family, ranging from relatively trivial epistaxis and telangiectasia to gastrointestinal, cerebral and pulmonary involvement. Evidence for successful therapy of HHT-related haemorrhage with oestrogens and progestones, and recent case reports outlining pulmonary complications of pregnancy in HHT, prompted us to review the outcome of 161 pregnancies in 47 affected women. HHT-related maternal complications developed in eleven patients, ten in the subgroup of 23 pregnancies in which pulmonary arteriovenous malformations (PAVMs) were present at the outset,

or documented in the two years following pregnancy. We present six cases of intrapulmonary shunt deterioration, two cases of fatal pulmonary haemorrhage and three cerebrovascular accidents related to pregnancy. A predisposition towards PAVMs in females was observed. Following the recent discovery of mutations in the endoglin gene in this disease, our data support a hypothesis of hormonal modification of the HHT phenotype. In addition, a significant excess of affected offspring are present in HHT families. We consider contributory aetiological factors, and discuss implications for patient management.

Introduction

Hereditary haemorrhagic telangiectasia is inherited as an autosomal dominant trait, and occurs with an incidence as high as 1 in 10 000 in certain populations.¹ The classical HHT features of familial nosebleeds and mucocutaneous telangiectases were described almost a century ago,^{2–4} but the most serious manifestations arise in cases with gastrointestinal, pulmonary and cerebral involvement. These vascular abnormalities range from pinpoint telangiectasia as in the mucocutaneous lesions, to arteriovenous malformations which display dilated arterial and venous elements, and a sac-like communication replacing the normal intervening capillary bed. When present in the pulmonary circulation, this results in

right to left shunting, arterial hypoxaemia, and a significant risk of paradoxical embolism.

The underlying genetic defect has been recently established: one of the genetic loci for the disease is located on chromosome 9,^{5,6} and is the gene for endoglin,⁷ a transmembrane glycoprotein expressed predominantly on endothelial cells, which apparently serves as a non-signalling transforming growth factor (TRF)- β receptor.⁸ The precise route by which this genetic defect leads to the HHT phenotype remains to be established. Correlations between the clinical phenotypes and the mutation segregating in each family may be made in the future, as clustering of pulmonary⁹ and cerebral¹⁰ cases has been described.

Address correspondence to Dr Claire Shovlin, Department of Genetics, Harvard Medical School, Alpert Building, 200 Longwood Ave, Boston, MA 02115, USA

© Oxford University Press 1995

However, a striking feature of this disease is the marked intrafamilial variation observed. Clues from the clinical environment may be instructive.

We report here the hitherto under-recognized alteration of the HHT phenotype in response to the female steroid hormones, particularly during pregnancy. This has implications for clinical management and elucidating the cellular pathogenesis of the disorder.

Pregnancy in HHT

From the age-of-onset figures (97% by age 35⁵), it is clear that HHT will affect many women by the time they reach child-bearing age. Via probands presenting for the diagnosis and treatment of PAVMs, a series of over 30 families has been assembled at the Hammersmith. From this cohort, we were able to review the medical outcome of 161 pregnancies in 47 women affected by HHT.

Maternal complications

The occurrence of significant complications was reviewed in conjunction with medical records and reports from physicians and obstetricians (Figure 1). Eleven major complications were observed. The most striking feature of these complications of pregnancy was their association with the presence or development of pulmonary arteriovenous malformations (PAVMs). In the 138 pregnancies in patients in whom PAVMs were never documented, or developed at

least 7 years after pregnancy, there was only one significant complication (a cerebrovascular event). This low complication rate is in contrast to the 23 pregnancies in 12 women from eight different families, in whom PAVMs were known to be present, or were diagnosed in the two years subsequent to a pregnancy. In this group of patients, there were six cases of apparent deterioration in intrapulmonary shunting, two cases of fatal pulmonary haemorrhage and two maternal cerebrovascular accidents. This difference is statistically significant ($p < 0.001$ using χ^2 2×2 with one degree of freedom).

Patient 1

A 26-year-old female presented in 1990 for the investigation of cyanosis and dyspnoea. She also gave a history of recurrent nose bleeds since childhood. On examination she was centrally cyanosed, clubbed and dyspnoeic. She displayed palatal telangiectasia consistent with a diagnosis of HHT. Examination of the cardiorespiratory system was otherwise unremarkable.

She was polycythaemic (Hb 18.9 g/dl) with hypoxaemia (PO₂ 6.5 kPa) and hypocapnia (PCO₂ 4.2 kPa). Her arterial oxygen saturation (SaO₂) was 85% and her ^{99m}Tc-MAA intrapulmonary right-to-left shunt¹¹ was 39% of the cardiac output, both measurements made in the supine posture. After standing for 10 min, SaO₂ fell to 74%. The forced vital capacity was 84% of predicted value (2.85 l) and the carbon monoxide diffusing capacity (TL_{CO}) was 41% of that predicted. A pulmonary angiogram demonstrated

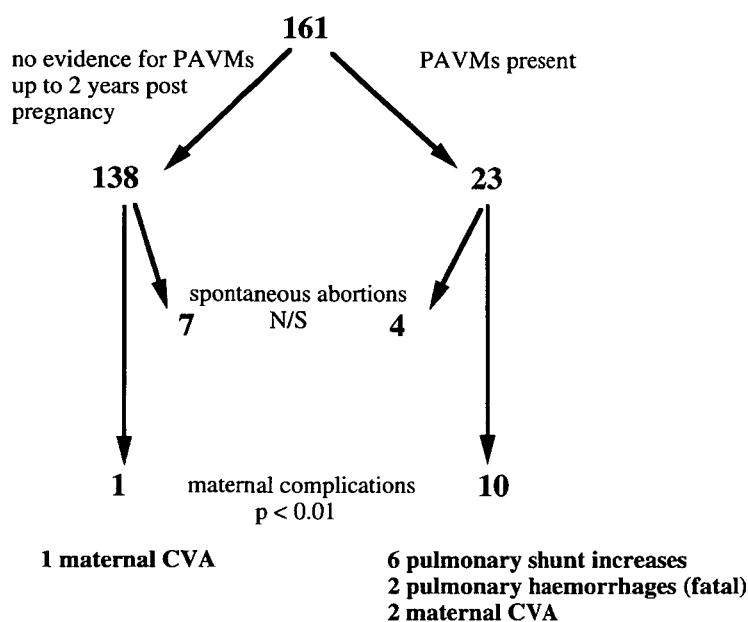


Figure 1. Outcome of 161 pregnancies in women affected by HHT. The pregnancies were divided into two groups according to the documentation of PAVMs in the mother either before, or in the two years following pregnancy. Statistical significance of differences between the two groups for spontaneous abortion rates, and maternal complications were calculated by χ^2 2×2 with one degree of freedom. N/S, not significant.

numerous large and small PAVMs throughout both lungs. Between February and September 1990, she underwent three embolizations occluding seven vessels with a total of 27 steel coils, with symptomatic relief. Her right-to-left shunt decreased stepwise to 21%, and SaO₂ improved both in the erect and supine postures (Table 1).

A year later, when 24 weeks pregnant, her post-embolization arterial saturations were well maintained. She reported that her recurrent nose bleeds had abated during the pregnancy. At 38 weeks gestation, she underwent a 40 min vaginal forceps delivery of a healthy male infant. Increasing dyspnoea and fatigue was first noted 2 months post partum. At 6 months post partum, she received a depot medroxyprogesterone contraceptive injection, and noted a further deterioration in her respiratory function. Her exercise tolerance dropped from 350 to 100 metres, and she required supplemental oxygen. On review at this time, her arterial oxygen

saturations, and right-to-left shunt measurements had returned to their pre-embolization figures (Table 1). Pulmonary angiography showed that new PAVMs had developed, in addition to the enlargement of existing vessels (Figure 2). However, these remained too small (<3 mm diameter) for further steel coil embolization.

Patient 2

The second case initially presented aged 13 years with epistaxis, cyanosis and dyspnoea. She had extensive PAVMs throughout both lungs, with an intrapulmonary shunt (supine) of 48% (Table 1). Over 2 years, she had multiple small feeding vessels occluded with steel coils (>30 vessels in five separate sessions). There was a modest improvement in the R-L shunt and pulmonary gas exchange (Table 1). Three and a half years later, she became pregnant. Her epistaxes had resolved prior to pregnancy and they did not recur. She remained well

Table 1 Arterial oxygenation, right to left shunt (as % cardiac output) and exercise capacity before and after pregnancy

	R-L shunt (%)	SaO ₂ % (supine)	SaO ₂ % (erect)	Max. exercise (W)	SaO ₂ % (max. ex.)
Patient 1					
Pre-embolisation	39	85	74	60	62
Pre-pregnancy	21	92	79	90	73
Post-pregnancy	30	87	75	75	68
Patient 2					
Pre-embolisation	48	78	65	75	52
Pre-pregnancy	32	84	73	100	40
Post-pregnancy	50	50	53	200 m*	46

* 200 m walk on the level.

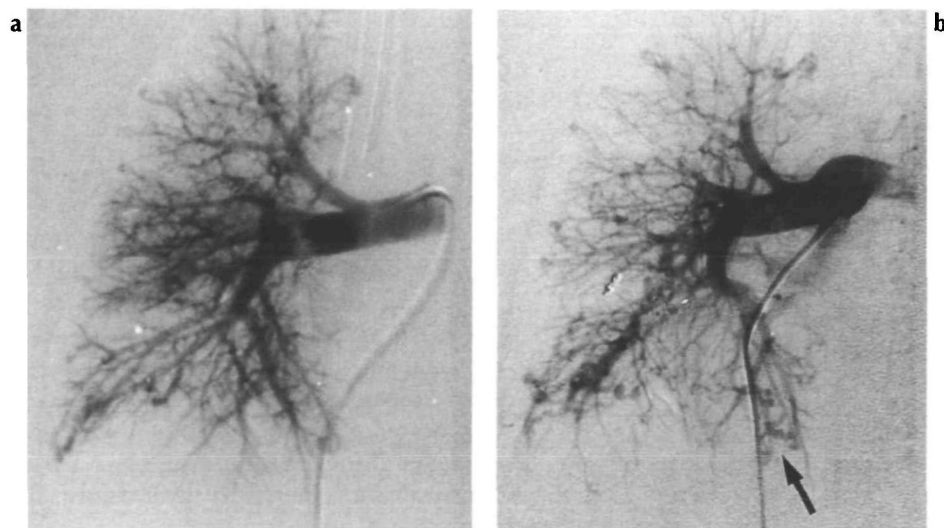


Figure 2. Right lung pulmonary arteriograms of patient 1, using a digital subtraction technique. **a** Arteriogram from February 1990 (12 months prior to pregnancy): on the left side, multiple small pulmonary arteriovenous malformations are scattered throughout the lung field. These were embolized with a total of 27 steel coils (see text). **b** Arteriogram from February 1993 (15 months post pregnancy): enlargement of PAVMs on the right is noted, most noticeably in the lower lobe (arrowed).

during pregnancy, but went into premature labour at 33 weeks, and had a forceps-assisted delivery of a healthy male infant. Post partum she experienced severe headaches, but a CT scan revealed no acute changes. The headaches settled. When assessed twelve weeks post delivery, considerable deterioration in R–L shunt, arterial oxygenation and exercise capacity had occurred. (Table 1).

Patient 3

A healthy 17-year-old woman, from a previously reported HHT family (F⁵), became pregnant. The first trimester was uneventful. She felt disproportionately faint from 3 months gestation, and noted dyspnoea occurring from the fourth month, increasing in the eighth month of pregnancy. Cyanosis was observed post delivery, (PO₂ 5.9 kPa [SaO₂ 78%]): later she had multiple PAVMs embolized in four sessions with a reduction in R–L shunt from 62 to 29%. The oral contraceptive pill was subsequently successfully tolerated.

Patient 4

A 28-year-old presented with episodes of haemoptysis two months after a 4 week gestation miscarriage. Three years earlier, she had had a miscarriage, followed by an uneventful pregnancy. Her SaO₂ was 91% (supine), 90% (erect posture) and 88% on maximal exercise. Her R–L shunt was 18%. At pulmonary angiography, two large right mid zone AVMs were embolized. Her SaO₂ improved to 95% in the erect and supine postures, and the R–L shunt decreased to 5%. A year later, she had another uneventful pregnancy without any deterioration in pulmonary gas exchange. Her epistaxes were worse during each pregnancy.

Patient 5

A fifth woman had a thorough pre-employment assessment at the age of 19, and no abnormalities were found. The following year she became pregnant. In the 14-week duration of the pregnancy, she noticed the development of severe nose bleeds which she had not experienced previously. Repeat respiratory investigations the following year now revealed the presence of hypoxaemia (SaO₂ 94% (erect posture) and 93% on maximal exercise). At pulmonary angiography, two PAVMs in the right mid zone were embolized with subsequent resolution of the hypoxaemia.

Patient 6

A woman with a family history of HHT was noted to be cyanosed at 2.5 years of age. At the age of nine years, pulmonary angiography showed AVMs for which she underwent resection of the left lower

lobe. She became pregnant at 17 years and was delivered by Caesarian section. She had miscarriages at the ages of 19 and 20 years, and a tubal ligation at 21 years. At 29 years she presented with severe cyanosis (SaO₂ 71% [erect posture]) and R–L shunt of 45%. At pulmonary angiography, 11 AVMs were embolized, with a modest improvement in SaO₂ (79%) and R–L shunt (41%).

Patients 7–11

Patients 1–6 reported above were from different HHT families; except for patient 2, all had affected female family members who had had successful pregnancies with no complications. However, in two of the families, different complications of pregnancy were observed in other individuals:

In one of the above cases, fatal pulmonary haemorrhage occurred in two other members of the family. In the first, a fatal pulmonary haemorrhage occurred during the first pregnancy. In the second, a 19-year-old, minor haemoptysis was first noted during the second trimester of her first pregnancy. A fatal pulmonary haemorrhage subsequently occurred near term.

The mother of patient 3 had two successful pregnancies, despite reporting cyanosis since childhood. She suffered a cerebrovascular accident in the fifth month of gestation of her third pregnancy. A lumbar puncture showed no evidence of subarachnoid bleeding. She refused treatment for her PAVMs. At the time of her most recent review, her SaO₂ was 81% (erect posture) and 77% (supine).

Two other cerebral events occurred in the cohort, but details are scanty. One occurred peripartum in the individual's fourth pregnancy, and was fatal. No radiology was available, but she was reported to be deeply cyanosed prior to the cerebral incident, suggesting the presence of untreated pulmonary AVMs. The other case occurred in an individual who has never displayed evidence of pulmonary arteriovenous malformations. It occurred six months after her third pregnancy and resulted in a transient hemiparesis from which she made a full recovery. She subsequently had two uncomplicated pregnancies, and has had no further cerebral complications.

In keeping with the available literature, no consistent trends were observed on the effects of pregnancy on the frequency of epistaxes, even amongst individuals in whom pregnancy led to an apparent deterioration of the pulmonary vascular bed. Further details on the natural history of epistaxes and telangiectasia in pregnancy await a formal prospective study.

Effects of HHT on the fetus

Eleven spontaneous abortions were recorded in the series of 161 pregnancies in affected individuals.

This did not represent an increase compared to UK population figures, confirming the findings by Goodman¹² who reviewed the obstetric outcomes of 40 HHT patients compared to 80 controls and found no statistical difference in miscarriage rates between the two groups in a retrospective series. Four spontaneous abortions were recorded in the group with PAVMs compared to seven in the non-PAVM group. This difference is not statistically significant.

It is of interest that an excess of affected individuals in the offspring of parents with HHT was observed in the cohort (Table 2). The overall development of HHT was documented in 80 of the 151 surviving offspring of the 47 women in the study. Earlier generations for which no obstetric records but complete family histories were available, were also reviewed to ascertain the status of the offspring of HHT-parents. To exclude an ascertainment bias by the inclusion of affected probands, these were re-assigned equally to the affected and unaffected groups of their respective sibships ($n=27$). In view of the degree of age-related penetrance in HHT (0% at birth, 80% by age 12, 97% by age 35⁵), the number of affected offspring was still higher than that expected for a population which included 39 children under the age of 12, 120 individuals between 12 and 35 years, and 138 over 35 years (see legend to Table 2 for calculations). The same trend was observed whether the affected parent was male or female. The overall excess in offspring from all HHT-

affected parents was statistically significant ($\chi^2=14.6$, $p<0.01$ using 2×2 with one degree of freedom).

Gender bias for PAVMs

The overall incidence of PAVMs displayed a female predominance. PAVMs are estimated to be present in less than 20% of affected individuals.¹ In the Hammersmith series of 47 HHT-related PAVMs, a female: male ratio of 1.6:1 was observed. Although this difference is not statistically significant, the combination with other published series¹³⁻¹⁵ gives a total of 185 female and 95 male cases; ($\chi^2=17.8$, $p<0.01$ using 2×2 with one degree of freedom).

Discussion

Our series emphasizes that pregnancy in patients with HHT and PAVMs may be hazardous. Pulmonary haemorrhage presenting as spontaneous massive haemothoraces is now well recognized.^{15,16} In contrast, structural or functional deteriorations of the pulmonary vascular bed have been viewed hitherto as isolated cases: one symptomatic,¹⁷ one radiographic¹⁸ and one increase in right-to-left shunt post partum.¹⁹ In the last of these cases, a 21-year-old woman with a history of multiple PAVMs presented at 31 weeks gestation with worsening cyanosis, and

Table 2 Diagnosis in offspring of an HHT-affected parent

Affected parent	Offspring (n)	Ages of offspring (years)			HHT status of offspring					
		<12	12-35	>35	Observed		Corrected		Expected	
					Affected	Other	Affected	Other	Affected	Other
Mother	164	14	83	67	97*	67	88.5	75.5	72	92
Father	133	25	37	71	77**	56	72	61	55.8	77.2
Either	307	39	120	138	174***	123	161	136.5	127.8	167.2

Offspring of HHT patients were analysed twice, once according to the sex of the transmitting parent, and once irrespective of parental sex. The observed number reflects the individuals' status when assessed at the ages described. The corrected number of affecteds takes into account that an affected member of each family was the proband leading to family identification. Where this individual was part of a sibship used in these assessments, they were assigned equally to the affected and unaffected groups from the calculations to eliminate this bias (*17 for mothers, **10 for fathers). The expected number of affecteds for each parental group was calculated by separating the age groups to enable the use of published penetrance values of 80% by 12 years, 97% by 35 years (calculated from this population,⁵ in keeping with other estimates¹. Hence expected number of affecteds for each age group:

$$\begin{aligned}
 <12 \text{ years} & \frac{(\text{number of cases } <12 \text{ years}) \times (0.8 + 0) \times 50\%}{2} \\
 12-35 \text{ years} & \frac{(\text{number of cases } 12-35 \text{ years}) \times (0.8 + 0.97) \times 50\%}{2} \\
 >35 \text{ years} & (\text{number of cases } >35 \text{ years}) \times 0.97 \times 50\%
 \end{aligned}$$

suffered a further shunt increase (49% to 57% [erect posture]) in the two weeks following an emergency Caesarian section.

Alterations of arteriovenous malformations during pregnancy is not confined to the pulmonary circulation. Deterioration is observed in most vascular beds, including hepatic,²⁰ cerebral^{21,22} and tongue.²³ In contrast, epistaxis is reported to improve during pregnancy.²⁴ Whilst HHT-related telangiectases have not been systematically reviewed, deterioration during pregnancy in cutaneous haemangiomas²⁵ or telangiectases associated with other high oestrogen states such as liver disease have been observed.

The systemic haemodynamic changes of pregnancy may be sufficient to account for the increased incidence of haemorrhage from structurally abnormal and fragile vessel walls (during pregnancy, the cardiac output and vascular volume rise by up to 40% at term^{26,27}). However, most of the complications we report are not haemorrhagic events, but represent the accelerated development of an abnormal vascular structure in the pulmonary circulation. An attractive hypothesis is that the abnormal HHT vessels, either when macroscopically normal, or in the early stages of the dilatation process,²⁸ display a predisposition to dilate as part of the fall in systemic and pulmonary vascular resistance which accompanies the increased vascular volume.^{26,27} This could result in the enlargement of existing lesions or their appearance *de novo*.

It is presumed that the haemodynamic events are the result of the altered concentrations of circulating oestrogens and/or progesterones, as many of the cardiovascular associations of pregnancy (sustained systemic vasodilatation, attenuated angiotensin II response, and increased cardiac output) can be reproduced in sheep by chronic or acute infusions of oestradiol-17 β ,²⁹ and independent progesterone effects on vasodilatation and red-blood-cell volume have been observed.²⁷ However, there is also increasing evidence for a localized hormonal influence on the vascular bed in HHT. These include our report of an increased frequency of PAVMs in females; the case reports of HHT-related epistaxis worsening in the reduced oestrogen states of the menopause,^{24,30} on the low-dose oestrogen-based oral contraceptive pill,³¹ and during menstruation;^{24,30} and the efficacy of treatment regimes based on higher doses of oestrogens and progesterones for HHT epistaxis and gastrointestinal bleeding.^{32–37} The minor variations in regional blood flow and blood volume which have been observed during the menstrual cycle³⁸ or in postmenopausal hormone replacement,³⁹ are unlikely to account for these clinical observations.

Two groups of observations on direct hormonal interactions are pertinent. In non-HHT settings, oestrogens have been shown to alter endothelial cell constituents,⁴⁰ and to induce changes in extracellular

matrix components.⁴¹ One could therefore postulate that the HHT vessels display a deranged response to the hormonal stimuli, resulting in vasodilatation. Evidence for this includes alterations in the HHT vascular wall following oestrogen and progesterone treatment,^{35,42} the further deterioration of PAVMs coinciding with the administration of a depot progesterone in one of our cases (which parallels observations that the restoration of the pressor response to angiotensin II post partum may be prevented by the administration of exogenous progesterone⁴³), and in particular, the detection of progesterone receptors in the skin of four individuals with HHT (two male, two female), but not in normal controls.⁴⁴

The recent description of mutations in the gene for endoglin⁷ provides a potential pathway for such hormonal influences. Endoglin is a homodimerizing transmembrane glycoprotein which binds TGF- β 1 and β 3.⁸ To date, no direct signalling function of the molecule has been described. Instead, it is proposed that endoglin modifies the presentation of ligand to the signalling complex comprised of Type I and Type II TGF- β receptors.⁵⁴ Mutations in the endoglin gene would thus be predicted to interfere with the transduction of an induced TGF- β signal in vascular endothelial cells. Amongst the plethora of proposed functions for the TGF- β signal transduction pathway, the altered secretion of extracellular matrix (ECM) and ECM receptors by endothelial cells, and the alteration of the endothelial cell cycle state could contribute to the vasodilatation observed in HHT, though the precise mechanism remains conjectural.⁴⁵ A null or 'two-hit' hypothesis, with somatic loss of the normal endoglin allele as a prerequisite for pathogenic vasodilatation, has been proposed.⁷ We favour an alternative hypothesis in which the single germline mutation may perturb the activity of endoglin, either by reduction in the number of wildtype homodimers, or via endoglin heterodimers which incorporate the mutant protein.⁴⁶ Thus any stimuli which increase the local concentration of activated TGF- β would have the potential to exacerbate the disease phenotype. The secretion of TGF- β in response to blood vessel injury or mechanical stress⁸ could contribute to the development of diseased vessels at specific sites. Since oestradiol 17- β induces the secretion of TGF- β from endothelial cells,⁴⁷ and a synthetic progestin has been shown to increase TGF- β secretion by up to 90-fold,⁴⁸ we would suggest that the additional modifications of the HHT phenotype which we describe may result from direct interactions of these hormones with the TGF- β interface during pregnancy.

Such considerations are unlikely to account for the post-partum deterioration of PAVMs observed in patient 1. This observation is paradoxical, since all of the hormonal and cardiovascular changes of

pregnancy should have regressed by this time. Indeed, clinical scenarios reflect worsening vasoconstriction in the post-partum state, for example in association with pre-eclampsia in Eisenmenger's syndrome⁴⁹ or in the pathogenesis of primary pulmonary hypertension.⁵⁰ One possible explanation could be that the PAVMs, which occur predominantly in the lower lung,^{9,51} experience extravascular compression from the uterus until delivery.

Fetal-placental interface

The lack of an increase in the rate of spontaneous abortion, or placenta-related complications observed by us and others¹² is surprising in the face of the high levels of endoglin expression in the placenta. Indeed, endoglin may be considered as an immunological marker of the syncytiotrophoblast.⁵² However, this structure derives from fetal tissues, and studies have demonstrated that the expression of endoglin in the decidua and maternal placental blood vessels is relatively low.⁵² Thus placental involvement will predominantly reflect the HHT status of the fetus, not the mother, and one might predict problems only in cases where the fetus was affected by HHT.

To our knowledge, no systematic review of placentas from HHT patients has been performed. In one placenta from an HHT mother which we were able to analyse, no gross abnormalities were detected, but to date, the HHT status of her infant is unknown. More importantly, it might have been predicted that there may be an excess of invasive choriocarcinomas in mothers with HHT-affected fetuses, but this was observed neither by us, nor in a previous series.¹²

Indeed, our observations display a significant excess of affected offspring from parents who have HHT, even when classifying all 'status unknown' individuals as unaffecteds. As endoglin is upregulated on cytotrophoblast cells at the time they invade the uterus,⁵² one could postulate that endoglin mutations are advantageous in establishing the placental bed and reduce the frequency of failed implantation of the fertilized zygote.

Clinical implications

With better knowledge of the natural history of pregnancy in HHT, more pertinent counselling can be offered to the patient. The data from our series suggests that for individuals in whom PAVMs are not present, pregnancy itself may be undertaken without increased risk. We acknowledge that our families have an *intrinsic selection bias* (the presence of PAVMs in a proband). It is therefore possible that the non-PAVM patients in our series are less at risk for other HHT complications than affected individuals

in 'non-PAVM' HHT families and this would be supported by an apparent under-representation of gastrointestinal involvement in our series.

Most importantly, our experience suggests that when PAVMs are present, pregnancy is hazardous. We advise that all individuals with HHT, and particularly, female HHT patients contemplating pregnancy, should be offered screening for PAVMs, with a minimum of a chest radiograph, and standing and supine arterial oxygen saturations. Such a screening strategy is vital because treatment of PAVMs with coil embolization has been shown to decrease the incidence of paradoxical embolism, and greatly reduce arterial hypoxaemia.^{9,53} However, it should be recognized that once PAVMs have been diagnosed, even after apparently successful treatment, pregnancy may precipitate a deterioration in the vascular bed, and should be undertaken with obstetric caution.

Acknowledgements

The authors would like to thank the family members, and their general practitioners. We are grateful to Dr T Krausz, Department of Histopathology, Royal Postgraduate Medical School for the analysis of the HHT placenta. CLS was supported by a Wellcome Trust Training Fellowship.

References

1. Plauchu H, de Chadarevian JP, Bideau A, Robert J-M. Age-related profile of hereditary hemorrhagic telangiectasia in an epidemiologically recruited population. *Am J Med Genet* 1989; **32**:291–7.
2. Rendu H. Epistaxis repetees chez un sujet porteur de petits angiomes cutanes et muqueux. *Gaz Hop (Paris)* 1896; **135**:132–3.
3. Osler W. On a family form of recurring epistaxis, associated with multiple telangiectases of the skin and mucous membranes. *Bull Johns Hopkins Hosp* 1901; **12**:333–7.
4. Weber F. Multiple hereditary developmental angiomas (telangiectases) of the skin and mucous membranes associated with recurring haemorrhages. *Lancet* 1907; **2**:160–2.
5. Shovlin CL, Hughes JMB, Tuddenham EGD, Temperley I, Perembelon YFN, Scott J, Seidman CE, Seidman JG. A gene for hereditary haemorrhagic telangiectasia maps to chromosome 9q3. *Nature Genet* 1994; **6**:205–9.
6. McDonald MT, Papenberg KA, Ghosh S, *et al.* A disease locus for hereditary haemorrhagic telangiectasia maps to chromosome 9q33–34. *Nature Genet*, 1994; **6**:197–204.
7. McAllister KA, Grogg KM, Johnson DW, *et al.* Endoglin, a TGF- β binding protein of endothelial cells, is the gene for hereditary haemorrhagic telangiectasia type 1. *Nature Genet* 1994; **8**:345–51.
8. Cheifetz S, Bellon T, Cales C, Vera S, Bernabeus C, Massague J, Letarte M. Endoglin is a component of the

- transforming growth factor- β receptor system in human endothelial cells. *J Biol Chem* 1992; **267**:19027–30.
9. Hughes JMB, Allison DJ. Pulmonary arteriovenous malformations: the radiologist replaces the surgeon. *Clin Radiol* 1990; **41**:297–8.
 10. King CR, Lovrien EW, Reiss J. Central Nervous system arteriovenous malformations in multiple generations of a family with hereditary hemorrhagic telangiectasia. *Clin Genet* 1977; **12**:372–81.
 11. Whyte MKB, Peters AM, Hughes JMB, Henderson BL, Bellingham GJ, Jackson JE, Chilvers ER. Quantification of right-to-left shunt at rest and during exercise in patients with pulmonary arteriovenous malformations. *Thorax* 1992; **47**:790–6.
 12. Goodman RM, Gresham GE, Roberts P. Outcome of pregnancy in patients with hereditary hemorrhagic telangiectasia. *Fertility and Sterility* 1967; **18**:272–7.
 13. Dines D, Arms RA, Bernatz PA, Gomes MR. Pulmonary arteriovenous fistulas. *Mayo Clin Proc* 1974; **49**:460–5.
 14. Dines D, Seward J, Bernatz P. Pulmonary arteriovenous fistulas. *Mayo Clin Proc* 1983; **58**:176–81.
 15. Ference BA, Shannon TM, White RI, Zawin M, Burdge CM. Life threatening pulmonary hemorrhage associated with pulmonary arteriovenous malformations and hereditary hemorrhagic telangiectasia. *Chest* 1994; **106**:1387–92.
 16. Laroche CM, Wells F, Schneerson J. Massive hemothorax due to enlarging arteriovenous fistula in pregnancy. *Chest* 1992; **101**:1452–4.
 17. Gammon R, Miska A, Keller F. Osler-Weber-Rendu disease and pulmonary arteriovenous fistulas. Deterioration and embolotherapy during pregnancy. *Chest* 1990; **98**:1522–4.
 18. Hoffman R, Rabens R. Evolving pulmonary nodules: Multiple pulmonary arteriovenous fistulas. *Am J Radiol* 1974; **120**:861–4.
 19. Swinburne AJ, Fedulla AJ, Gangemi R, Mijangos JA. Hereditary telangiectasia and multiple pulmonary arteriovenous fistulas. Clinical deterioration during pregnancy. *Chest* 1986; **89**:459–60.
 20. Livneh A, Langevitz P, Morag B, Catania A, Pras M. Functionally reversible hepatic arteriovenous fistulas during pregnancy in patients with hereditary hemorrhagic telangiectasia. *South Med J* 1988; **81**:1047–9.
 21. Neau JP, Roulades G, Bataille B, Muckensturm B, Rivasseau T, Gil R, Lefevre JP, Salles M. Recurrent intracranial haematomas disclosing Rendu-Osler disease in a pregnant woman. *Neurochirurgie* 1988; **34**:64–7.
 22. Lesser BA, Wendt D, Miks VM, Norum RA. Identical twins with hereditary hemorrhagic telangiectasia concordant for cerebrovascular arteriovenous malformations. *Am J Med* 1986; **81**:931–4.
 23. Marusov AP, Baitiakov VV. Hemorrhage from the root of the tongue of a pregnant woman with Rendu-Osler-Weber disease. *Akusherstvo i Ginekologiya*, 1987; **2**:73–4.
 24. Harrison DFN. Familial haemorrhagic telangiectasia. *Q J Med* 1964; **57**:25–38.
 25. Wilkin JK, Smith JG, Cullison DA, Peters GE, Rodriguez-Rigau LJ, Feucht CL. Unilateral dermatomal superficial telangiectasia. *J Am Acad Dermatol* 1983; **8**:468–77.
 26. Moore LG, Reeves JT. Pregnancy blunts pulmonary vascular reactivity in dogs. *Am J Physiol* 1980; **239**:H297–H301.
 27. Moore LG. Circulation in the pregnant and non-pregnant state. In Weir EK, Reeves JT, eds. *Pulmonary Vascular Physiology and Pathophysiology*, Lung Biology in Health and Disease Series Vol 38. New York, Marcel Dekker, 1989:135–73.
 28. Braverman IM, Keh A, Jacobson BS. Ultrastructure and three dimensional organisation of the telangiectases of hereditary hemorrhagic telangiectasia. *J Invest Dermatol* 1990; **95**:422–7.
 29. Magness RR, Parker CR, Rosenfeld CR. Systemic and uterine responses to chronic infusion of estradiol-17 β . *Am J Physiol* 1993; **265**:E690–8.
 30. Koch HJ, Escher GC, Lewis SJ. Hormonal management of hereditary hemorrhagic telangiectasia. *JAMA* 1952; **149**:1376–80.
 31. Rowley PT, Kurnick J, Cheville R. Hereditary haemorrhagic telangiectasia: aggravation by oral contraceptives? *Lancet* 1970; **1**:474–5.
 32. Harrison DFN. Use of oestrogens in treatment of familial hemorrhagic telangiectasia. *Laryngoscope* 1982; **92**:314–19.
 33. Ito S, Hirono S. Two cases of hereditary haemorrhagic telangiectasia showing rapid improvement of epistaxis after combination therapy of estrogen and progesterone. *Rinsho Ketsueki* 1982; **23**:1205–10.
 34. Vase P, Lorentzen M. Histological findings following oestrogen treatment of hereditary haemorrhagic telangiectasia. A controlled double-blind investigation. *J Laryngol Otol* 1983; **97**:427–9.
 35. van Cutsem E. Oestrogen-progesterone, a new therapy of bleeding gastrointestinal vascular malformations. *Acta Gastro-Enterologica Belgica* 1993; **56**:2–10.
 36. Flessa HC, Glueck HI. Hereditary hemorrhagic telangiectasia (Osler-Weber-Rendu disease). Management of epistaxis in nine patients using systemic hormone therapy. *Arch Otolaryngol* 1977; **103**:148–51.
 37. McGee RR. Estrogen-progesterone treatment for gastrointestinal bleeding in hereditary hemorrhagic telangiectasia. *South Med J* 1979; **72**:1503.
 38. Bartelink ML, Wollersheim H, Theeuwes A, van Duren D, Thien T. Changes in skin blood flow during the menstrual cycle: the influence of the menstrual cycle on the peripheral asculation in healthy female volunteers. *Clin Sci* 1990; **78**:527–32.
 39. Tankersley CG, Nicholas WC, Deaver DR, Mikita D, Kenney WL. Estrogen replacement in middle aged women: thermoregulatory responses to exercise in the heat. *J Appl Physiol* 1992; **73**:1238–45.
 40. Rosenfeld CR, Kamm KE. Myosin heavy chain (MHC) isoforms are regulated differently in myometrium (MYO) and uterine artery smooth muscle (UA) in ovine pregnancy and the puerperium (Abstract). *Biophys J* 1993; **64**:34.
 41. Fischer GM, Swain ML. Effects of estradiol and progesterone on the increased synthesis of collagen in atherosclerotic rabbit aortas. *Atherosclerosis*, 1985; **54**:177–85.
 42. Menefee MG, Flessa HC, Glueck HI, Hogg SP. Hereditary haemorrhagic telangiectasia. *Arch Otolaryngol* 1975; **101**:246–51.
 43. Worley RJ, Gant NF, Everett RB, MacDonald PC. Vascular responsiveness to pressor agents during human pregnancy. *J Reprod Med* 1979; **23**:115–28.
 44. Richtsmeier W, Weaver G, Streck W, Jacobson H, Dewell R, Olson J. Estrogen and progesterone receptors in hereditary hemorrhagic telangiectasia. *Otolaryngol Head Neck Surg* 1984; **92**:564–70.
 45. Shovlin CL, Scott J. Inherited diseases of the vasculature. *Ann Rev Physiol* 1996; **58**:483–507.

46. Shovlin CL, Hughes JMB, Scott J, Seidman CE, Seidman JG. The molecular basis of hereditary hemorrhagic telangiectasia. In preparation.
47. Gong Y, Murphy LC, Murphy LJ. Hormonal regulation of proliferation and transforming growth factors gene expression in human endometrial adenocarcinoma xenografts. *J Ster Biochem Mol Biol* 1994; **50**:13–19.
48. Colletta AA, Wakefield LM, Howell FV, Danielpour D, Baum M, Sporn MB. The growth inhibition of human breast cancer cells by a novel synthetic progestin involves the induction of transforming growth factor beta. *J Clin Invest* 1991; **87**:277–83.
49. Jewett JF. Pulmonary hypertension and pre-eclampsia. *N Engl J Med* 1979; **301**:1063–4.
50. Dawkins KD, Burke CM, Billingham ME, Jamieson SW. Primary pulmonary hypertension and pregnancy. *Chest* 1986; **89**:383–8.
51. Moore BP. Pulmonary arteriovenous fistula. *Thorax* 1969; **24**:381.
52. St-Jacques S, Forte M, Lye SJ, Letarte M. Localisation of endoglin, a transforming growth factor- β binding protein, and of CD44 and integrins in placenta during the first trimester of pregnancy. *Biol Repro* 1994; **51**:405–13.
53. White RI. Pulmonary arteriovenous malformations: How do we diagnose them and why is it important to do so? *Radiology* 1992; **182**:633–5.

